

# Scientific Session of the General Meeting of the RAS Members “The Role of Science in Overcoming Pandemics and Postcrisis Development of Society”

## Diffuse Lung Disease in Convalescents of COVID-19

A. V. Averyanov<sup>a,\*</sup> and O. V. Danilevskaya<sup>a,\*\*,#</sup>

<sup>a</sup> Pulmonology Research Institute, Federal Medical–Biological Agency, Moscow, Russia

\*e-mail: averyanovav@mail.ru

\*\*e-mail: danless@mail.ru

Received January 31, 2022; revised February 11, 2022; accepted March 9, 2022

**Abstract**—The most common causes of diffuse interstitial lung damage following COVID-19, often either imitate it but have a different nature or remain due to prolonged persistence of SARS-CoV-2 in the lower respiratory tract. A diagnostic algorithm is proposed to make mostly a correct diagnosis, the key element of which is study of the bronchoalveolar lavage fluid.

**Keywords:** COVID-19, post-COVID lung disease, interstitial lung disease, persistence of SARS-CoV-2, bronchoalveolar lavage

**DOI:** 10.1134/S1019331622040037

Just a few months after the beginning of the COVID-19 pandemic, doctors were faced with cases of recurrent diffuse interstitial processes in the lungs, which resembled acute coronavirus infection caused by SARS-CoV-2 in terms of clinical, radiological, and often laboratory features. Such patients were hospitalized anew to covid hospitals with multiple courses of etiotropic and immunosuppressive therapy despite mostly negative PCR analysis results for coronavirus in the nasopharyngeal and oropharyngeal swabs. Many patients did respond to treatment with corticosteroids and anticytokine drugs, but after completion, the disease returned in its previous form. In some patients, anti-inflammatory and immunosuppressive therapy had no effect; the disease either persisted or progressed, sometimes leading to death. As the number of people recovering from COVID-19 grows, there are increasingly more cases of interstitial lung damage in the post-COVID period. In this article, we analyze the range of pathological processes in the lungs that develop after a new coronavirus infection and propose a diagnostic algorithm that in most cases makes it possible to establish the exact cause of the disease and prescribe the correct treatment.

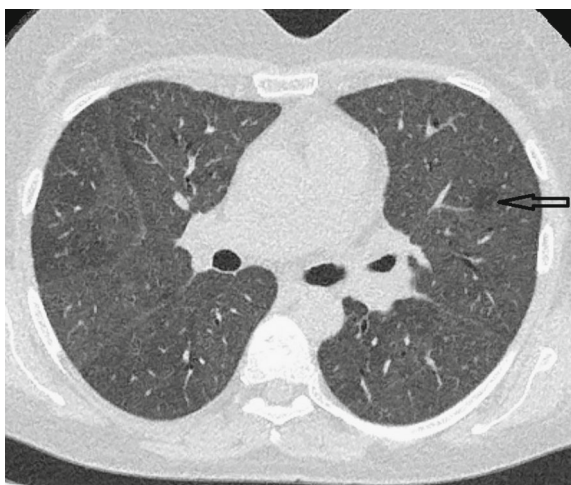Based on our own experience with patients with persistent diffuse interstitial processes in the lungs in

the post-COVID period, we conclude that they can be divided into four main groups.

(1) *Interstitial pneumonia caused by opportunistic pathogens.* One of the most common opportunistic infections we encountered was *P. jirovecii* pneumonia. Note that its causative agent led to interstitial damage not only in individuals with initial immunodeficiency but also in some patients with severe COVID-19 who underwent to powerful, often prolonged and uncontrolled immunosuppression. Clinically, the disease manifested by febrile or subfebrile fever; diffuse “ground-glass opacity” areas (Fig. 1), often with air traps on the chest CT scan; leukopenia and lymphopenia; and an increase in the level of C-reactive protein and interleukin-6 in blood tests; i.e., it almost completely repeated the features of COVID-19. Several similar cases have already been described in the literature, including those occurring with signs of a “cytokine storm”; therefore, we should always be alert regarding *P. jirovecii* pneumonia in recurrent post-COVID lung damage [1, 2]. With the advent of highly sensitive test systems for the detection of SARS-CoV-2 RNA, any negative result of PCR analysis for COVID-19 in a patient with acute diffuse lung disease should be considered from the standpoint of a possible alternative diagnosis, primarily *P. jirovecii* pneumonia, including patients initially admitted to covid hospitals.

Back at the beginning of the pandemic, we described a case of severe pneumocystis pneumonia in an HIV-infected patient, mimicking COVID-19 in its manifestations [3]. The main method for diagnosing this infection is PCR analysis of bronchoalveolar

<sup>#</sup> RAS Corresponding Member Alexander Vyacheslavovich Averyanov, is Chief Researcher at the Pulmonology Research Institute of the Federal Medical–Biological Agency (FMBA) of Russia. Olesya Vasil’evna Danilevskaya, Dr. Sci. (Med.), is Learned Secretary at the same institute.

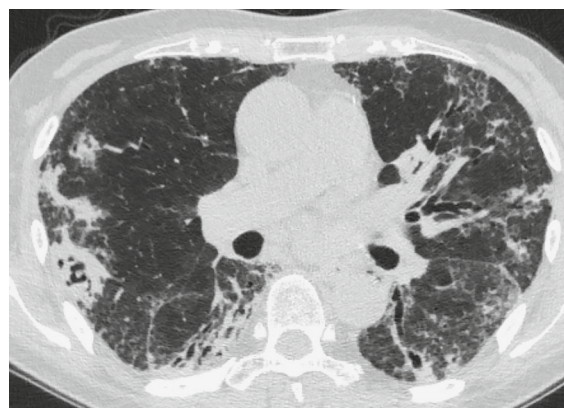

**Fig. 1.** Pneumocystis pneumonia that developed two months after COVID-19 in a long-term high-dose systemic glucocorticoid patient. Spilled areas of ground glass, totally filling the parenchyma of the lungs. Left: a single unaffected lobule (arrow).

lavage (BAL) fluid for *P. jirovecii*. Treatment of *P. jirovecii* pneumonia is traditional: high doses of trimethoprim/sulfamethoxazole in combination with systemic glucocorticoids.

The next possible subgroup of opportunistic pathogens of post-COVID lung damage are fungal infections, most often *Aspergillus* spp. Such an infection should be suspected in all patients with signs of persistent inflammation; the presence of consolidation zones in the lungs, surrounded by foci of drop-outs; and especially in the case of post-COVID cavities in the lungs (Fig. 2). The frequency of invasive aspergillosis in patients with severe COVID-19 reaches 30%, being one of the negative prognosis factors [4] if the problem was not recognized in time. In the future, after discharge from the hospital, it is pneumomycosis that may determine the picture of persistent lung damage. Methods for diagnosing invasive aspergillosis include culture of sputum or BAL fluid, determination of the level of galactomannan in blood or BAL fluid, and PCR testing for *Aspergillus* DNA from the bronchial contents, sputum, or BAL [5]. Voriconazole is used as a first choice drug.

Invasive candidiasis is the second most common fungal complication after COVID-19. In patients with acute coronavirus infection, representatives of the *Candida* genus—*C. albicans*, *C. tropicalis*, *C. parapsilosis*, *C. orthopsilosis*, and *C. glabrata*—are detected. In the post-COVID period, a significant change in the intestinal microbiome occurs and candida flora begins to predominate in it [6]. Its translocation can cause damage to many organs up to the central nervous system [7]. Diagnosis of pulmonary candidiasis is based on a cultural study of the BAL fluid, determination of



**Fig. 2.** Invasive pulmonary aspergillosis in a patient after severe COVID-19. In the lower lobe of the right lung, there is a thick-walled cavity with intracavitary inclusions (“rattle” symptom). Bilateral irregular consolidation foci on both sides, reticular changes.

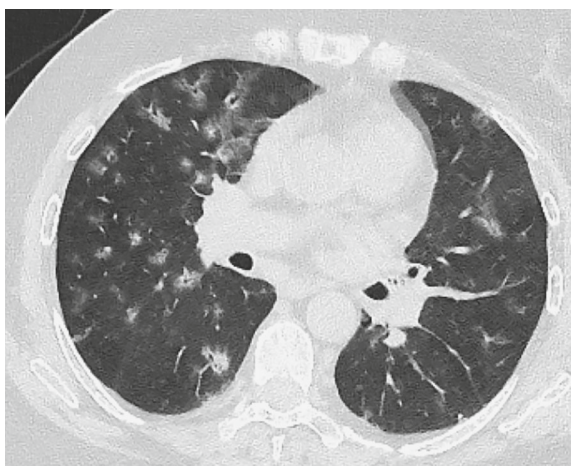
the mannan antigen (a candida cell wall oligosaccharide), and a PCR test for candida in the same substrate or (1-3)- $\beta$ -D-glucan in the blood serum. Echinocandins (anidulafungin, caspofungin, or micafungin) are frontline therapy for invasive candidiasis [8].

Cytomegalovirus pneumonia following COVID-19 is a rarer but possible case [9]; therefore, PCR testing of the blood and BAL for cytomegalovirus, in our opinion, should be included in the list of diagnostic tests when searching for opportunistic pathogens.

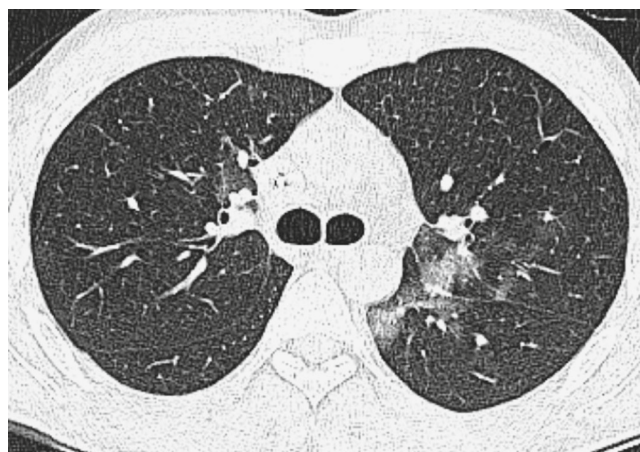
The revival of latent forms of tuberculosis after a new coronavirus infection has also been encountered in our practice; however, this process on a chest CT scan usually manifests itself in the form of multiple foci rather than diffuse interstitial changes and therefore is easier to diagnose.

Epstein–Barr virus, being a herpes virus, is present as a latent infection in 90% of the adult population [10]. Signs of reactivation of this viral infection were found in 66% of patients with symptoms of weakness, insomnia, headache, and myalgia after COVID-19 [11]. Perhaps this pathogen also plays a role in persistent lung disease in the post-COVID period after immunosuppressive therapy since Epstein–Barr-associated pneumonitis was previously described in immunocompromised patients [12].

(2) *Covid-induced vasculitis with lung involvement.* Today, experts have a very definite opinion that both SARS-CoV-2 and antiviral vaccines can induce a number of autoimmune diseases—Guillain–Barré syndrome, autoimmune thyroiditis, autoimmune hemolytic anemia, and vasculitis [13]. Thus far, the literature has described only a few cases of ANCA-associated vasculitis that occurred in the short term after COVID-19 or vaccination, both in the form of diffuse alveolar hemorrhages and as an infiltrative process



**Fig. 3.** ANCA-associated vasculitis occurring within one month of COVID-19 vaccination. Bilateral foci of ground-glass opacities and consolidations with peribronchovascular distribution.



**Fig. 4.** Persistent SARS-CoV-2 nine-month-long infection in a 25-year-old patient with a history of B-cell lymphoma who completed rituximab treatment just before falling ill with COVID-19. Bilateral ground-glass areas with subpleural and peribronchovascular distribution.

with cavitary formations in the lungs [14]. In our practice, we encountered at least two patients with signs of bilateral peribronchovascular attenuation in the lungs, detected on computed tomograms, with a persistent systemic inflammatory response after COVID-19 and vaccination against SARS-CoV-2 (Fig. 3). In both cases, a blood test for antibodies to proteinase-3 and myeloperoxidase made it possible to make a correct diagnosis without resorting to bronchoscopy and lung biopsy.

(3) *Interstitial lung disease caused by persistence of SARS-CoV-2.* After the publication of a meta-analysis [15] (it was carried out on the basis of 79 studies with the participation of 5340 patients) with an assessment of the viability of SARS-CoV-2 based on the results of biological cultures, it became clear that the new coronavirus, at least its strains that caused the first two waves of the disease, have a very short active phase in the infected body: beyond nine days from the onset of the disease, it was impossible to identify a live virus in any patient. However, there are patients in whom SARS-CoV-2 can persist for weeks or even months, causing both general inflammatory symptoms and recurrent interstitial lung disease (Fig. 4). These are patients with severe immunodeficiency of the cellular lymphocytic link, primarily with oncohematological diseases, especially those who received immunosuppressive therapy, primarily rituximab, prior to COVID-19 [16, 17]. Interestingly, in many of these patients, the PCR test for SARS-CoV-2 from the upper respiratory tract becomes negative, but viral RNA is detected in the bronchoalveolar lavage fluid or in the gastrointestinal tract [18, 19].

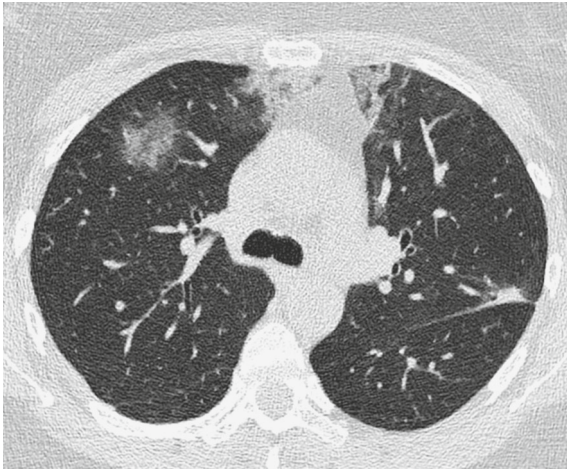In our practice, we encountered a patient with severe lymphopenia, fever, and recurrent ground-glass

opacities foci on computed tomography. Since it was impossible to use BAL, she underwent a bone marrow puncture, in which the PCR test for the new coronavirus gave a positive result five months after the acute infection. Thus, if persistent COVID-19 is suspected, PCR testing of BAL fluid, feces, or bone marrow (in the presence of lymphopenia) for SARS-CoV-2 should be performed to confirm a possible viral infection.

Treatment of patients with long-term persistent coronavirus infection is a difficult task. We have successfully used a combination of plasma exchange (at least 3 L of plasma) with plasma replacement of COVID-19 convalescents and a large dose of COVID-globulin in such patients. After the creation of antiviral monoclonal antibodies, there was hope that such patients could be completely cured by these drugs. The first such experience in treating a patient with a 300-day persistence of coronavirus by subcutaneous administration of Regen-COV antibodies has already been published [16].

(4) *COVID-induced interstitial lung disease (CI-ILD).* According to the first study, which retrospectively evaluated a cohort of such patients, CI-ILD signs were observed in 4.8% of patients discharged from the covid hospital. Although these patients are increasingly often found in the pulmonology clinic, neither a definition of the disease nor unified approaches to its management have been formulated thus far. Based on the time factor of the disease, considered in [20], we propose the following definition: “Post-COVID-19 interstitial lung disease is persistent interstitial inflammation lasting for more than six weeks after COVID-19, not associated with infection, as well as drug or other exogenous factors and systemic diseases.” This





**Fig. 5.** Interstitial lung disease induced by COVID-19 in a 43-year-old female patient. Recurring within six months bilateral ground-glass opacity and consolidation areas, completely disappearing after taking systemic steroids. The distribution of damage is subpleural and peribronchial. Computed tomography demonstrates the pattern of organizing pneumonia.

approach requires, in the first place, the exclusion of other possible causes of interstitial damage in the post-COVID period, which were mentioned above. Changes detected by computed tomography in patients with CI-ILD most often correspond to the pattern of organizing pneumonia (peribronchovascular and subpleural foci of consolidation and ground glass opacity (Fig. 5), which are in combination of halo sign or reverse halo sign). The second place in terms of frequency is occupied by the pattern of the cellular variant of nonspecific interstitial pneumonia (ground glass opacity areas with moderate reticular changes, predominantly subpleurally gravitating towards the basal regions). Histologically, these patients also show signs of organizing or nonspecific interstitial pneumonia with traces of diffuse alveolar damage. The main method of treatment for CI-ILD involves the administration of systemic glucocorticoids in medium doses with their slow, careful decrease (considering the control of the assessment of the diffusion capacity of the lungs, the main functional criterion for the course of the disease) [21]. In our clinic, in addition to systemic glucocorticoids in CI-ILD, we use short courses of cyclophosphamide at a dose of 200 mg/day for 3–5 days. We also use an inhaled surfactant (75 mg for 3 times a day) in combination with noninvasive lung ventilation during inhalations or alternating inhalation with breathing with exhalation resistance to straighten atelectatic areas of the lung tissue.

Despite our concerns at the beginning of the pandemic about the risks of developing severe pulmonary

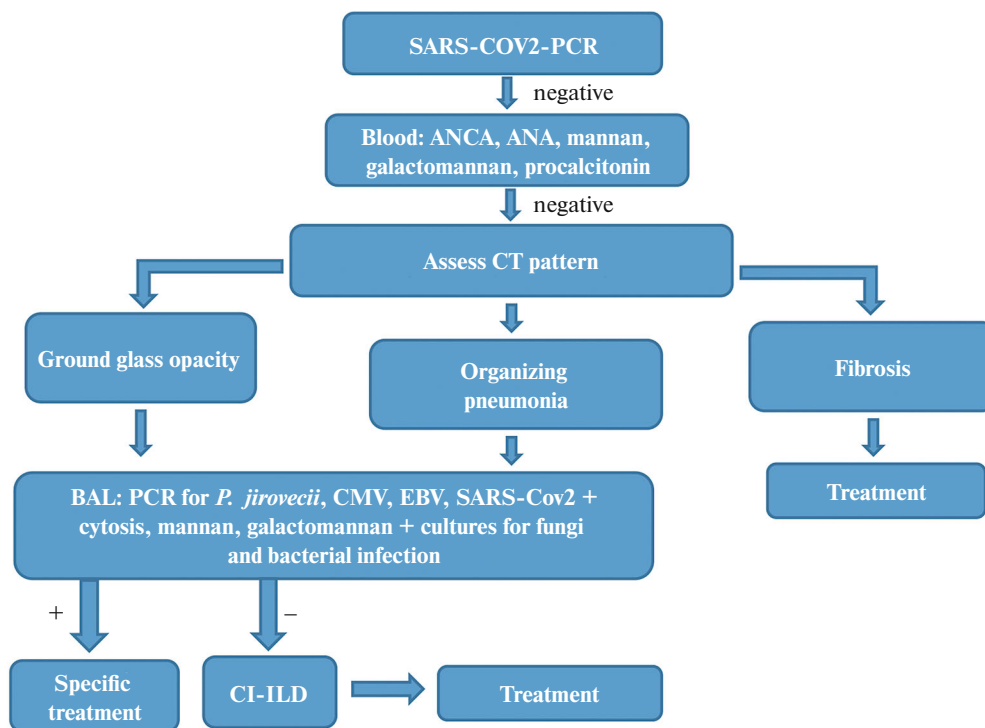
fibrosis after COVID-19, our experience suggests that pulmonary fibrosis after a new coronavirus infection is an extremely rare condition, which is observed only in patients who survived severe forms of the disease and, unlike idiopathic pulmonary fibrosis, does not tend to progress.

Among other possible causes of interstitial lung damage after COVID-19, one can discuss diseases associated not so much with the viral infection but with the complications of therapy. These include drug-induced interstitial lung disease, which can be caused by many of the drugs used, and alveolar hemorrhages as a result of taking anticoagulants. An important diagnostic tool, just like in most other cases of post-COVID-19 lung damage, is a cytological analysis of bronchoalveolar lavage fluid, in which lymphocytosis (with drug pneumonitis) or erythrocytosis (with alveolar hemorrhages) is found. Note that the cytological and PCR analysis of bronchial aspirates, often used in routine practice instead of BAL to speed up the bronchoscopy procedure, according to our data, in more than half of the cases does not make it possible to identify real pathogens or evaluate the cellular dominant of post-COVID lung pathology.

For the differential diagnosis of post-COVID diffuse lung damage, we use the diagnostic algorithm shown in Fig. 6; thanks to it, we managed to make an accurate diagnosis in almost all cases. At the first stage, we recommend a blood test for markers of autoimmune diseases (antineutrophil cytoplasmic antibodies, antinuclear antibodies) and bacterial infection (procalcitonin). A positive result most often brings closer making the diagnosis without invasive procedures. If the result is negative, further actions should be based on the features of computed tomography of the diffuse process pattern in the lungs. The pattern of fibrosis (reticular changes, traction bronchiectasis) without a ground-glass opacities and in the absence of inflammatory symptoms gives reasons to suspend further diagnostic search and focus on treatment. If inflammatory signs (ground glass opacity, consolidation, foci, etc.) are detected on a chest CT scan, the patient should undergo bronchoscopy and bronchoalveolar lavage with the range of studies discussed above. Exclusion of infections and other rarer causes allows the diagnosis of COVID-induced interstitial lung disease.

\* \* \*

Differential diagnosis of diffuse post-COVID lung disease is a difficult but solvable task. The most common causes of the ongoing interstitial process in the lung parenchyma after COVID-19 are opportunistic infections (fungal, pneumocystis, cytomegalovirus, tuberculosis), autoimmune diseases with lung damage, and persistence of SARS-CoV-2 infection in the lung tissue (usually in patients who previously received rituximab). If all these factors are excluded, it is highly



**Fig. 6.** ANA, antinuclear antibodies; ANCA, antineutrophil cytoplasmic antibodies; BAL, bronchoalveolar lavage; PCT, procalcitonin. Diagnostic algorithm for diffuse lung damage after COVID-19.

likely that the new interstitial lung disease is induced by COVID-19.

#### CONFLICT OF INTEREST

The authors declare that they have no conflicts of interest.

#### REFERENCES

- G. Viceconte, A. R. Buonomo, A. Lanzardo, et al., "Pneumocystis jirovecii pneumonia in an immunocompetent patient recovered from COVID-19," *Infect. Dis. (London)* **53** (5), 382–385 (2021). <https://doi.org/10.1080/23744235.2021.1890331>
- K. K. Chakravarthy, B. Cherukuri, S. Anne, et al., "An unusual case of severe pneumocystis jirovecii pneumonia (PJP) presenting as 'recurrent cytokine storm' following COVID-19," *Infection J. Assoc. Physicians India* **69** (5), 78 (2021).
- A. V. Aver'yanov, A. G. Sotnikova, and V. N. Lesnyak, "Pneumocystis pneumonia mimicking COVID-19," *Klin. Prakt.*, No. 2, 87–92 (2020).
- A. Apostolopoulou, Z. Esquer Garrigos, P. Vijayvargiya, et al., "Invasive pulmonary aspergillosis in patients with SARS-CoV-2 infection: A systematic review of the literature," *Diagnostics* **10** (10), Article no. 807 (2020). <https://doi.org/10.3390/diagnostics10100807>
- A. Abdoli, S. Falahi, and A. Kenarkoobi, "COVID-19-associated opportunistic infections: A snapshot on the current reports," *Clin. Exp. Med.* (2021). <https://doi.org/10.1007/s10238-021-00751-7>
- T. Zuo, X. Wu, W. Wen, and P. Lan, "Gut microbiome alterations in COVID-19," *Genomics, Proteomics, and Bioinformatics* (2021). <https://doi.org/10.1016/j.gpb.2021.09.004>
- M. A. Miranda, S. C. Sousa, and V. L. Montes, "Post-COVID-19 neurocandidiasis," *Neurol. Sci.* **9**, 1–2 (2021). <https://doi.org/10.1007/s10072-021-05515-5>
- A. Ghosh, A. Sarkar, P. Paul, and P. Patel, "The rise in cases of mucormycosis, candidiasis, and aspergillosis amidst COVID-19," *Fungal Biol. Rev.* **19** (5), 679–688 (2021). <https://doi.org/10.1016/j.fbr.2021.09.003>
- M. Shah, A. Kakar, A. Gogia, and S. Langer, "Convalescent plasma, cytomegalovirus infection, and persistent leukopenia in COVID-19 recovery phase: What is the link?," *J. Postgrad. Med.* **67** (2), 100–102 (2021). [https://doi.org/10.4103/jpgm.JPGM\\_1168\\_20](https://doi.org/10.4103/jpgm.JPGM_1168_20)
- M. Neves, J. Marinho-Dias, J. Ribeiro, and H. Sousa, "Epstein–Barr virus strains and variations: Geographic or disease-specific variants?," *J. Med. Virol.* **89**, 373–387 (2017). <https://doi.org/10.1002/jmv.24633>
- J. E. Gold, R. A. Okyay, W. E. Licht, and D. J. Hurley, "Investigation of long COVID prevalence and its relationship to Epstein–Barr virus reactivation," *Pathogens* **10** (6), Article no. 763 (2021). <https://doi.org/10.3390/pathogens10060763>

12. A. Sauter, C. Faul, M. Bitzer, et al., “Imaging findings in immunosuppressed patients with Epstein Barr virus-related B cell malignant lymphoma,” *AJR Am. J. Roentgenol.* **194** (2), W141–W149 (2010).  
<https://doi.org/10.2214/AJR.09.3264>
13. A. Dotan, S. Muller, D. Kanduc, et al., “The SARS-CoV-2 as an instrumental trigger of autoimmunity,” *Autoimmun. Rev.* **20** (4), 102792 (2021).  
<https://doi.org/10.1016/j.autrev.2021.102792>
14. T. Izci Duran, E. Turkmen, M. Dilek, et al. “ANCA-associated vasculitis after COVID-19,” *Rheumatol. Int.* **41** (8), 1523–1529 (2021).  
<https://doi.org/10.1007/s00296-021-04914-3>
15. M. Cevik, M. Tate, O. Lloyd, et al., “SARS-CoV-2, SARS-CoV, and MERS-CoV viral load dynamics, duration of viral shedding, and infectiousness: A systematic review and meta-analysis,” *Lancet Microbe* **2** (1), e13–e22 (2021).  
[https://doi.org/10.1016/S2666-5247\(20\)30172-5](https://doi.org/10.1016/S2666-5247(20)30172-5)
16. A. C. Drouin, M. W. Theberge, S. Y. Liu, et al., “Successful clearance of 300-day SARS-CoV-2 infection in a subject with B-cell depletion associated prolonged (B-DEAP) COVID by REGEN-COV anti-spike monoclonal antibody cocktail,” *Viruses* **13** (7), Article no. 1202 (2021).  
<https://doi.org/10.3390/v13071202>
17. V. Borges, J. Isidro, M. Cunha, et al., “Long-term evolution of SARS-CoV-2 in an immunocompromised patient with non-Hodgkin lymphoma,” *mSphere* **6** (4), e0024421 (2021).  
<https://doi.org/10.1128/mSphere.00244-21>
18. G. Caci, F. Minervini, C. Fechner, et al., “Bronchoalveolar lavage-detected SARS-CoV-2 infection in presence of serial negative nasopharyngeal swabs: A case report,” *Ann. Transl. Med.* **9** (7), Article no. 583 (2021).  
<https://doi.org/10.21037/atm-20-4307>
19. F. Hu, F. Chen, Z. Ou, et al., “A compromised specific humoral immune response against the SARS-CoV-2 receptor-binding domain is related to viral persistence and periodic shedding in the gastrointestinal tract,” *Cell. Mol. Immunol.* **17** (11), 1119–1125 (2020).  
<https://doi.org/10.1038/s41423-020-00550-2>
20. J. M. Wild, J. C. Porter, P. L. Molyneaux, et al., “Understanding the burden of interstitial lung disease post-COVID-19: The UK Interstitial Lung Disease-Long COVID study (UKILD-Long COVID),” *BMJ Open Respir. Res.* **8** (1), e001049 (2021).  
<https://doi.org/10.1136/bmjresp-2021-001049>
21. K. J. Myall, B. Mukherjee, A. M. Castanheira, et al., “Persistent post-COVID-19 interstitial lung disease: An observational study of corticosteroid treatment,” *Ann. Am. Thorac. Soc.* **18** (5), 799–806 (2021).  
<https://doi.org/10.1513/AnnalsATS.202008-1002OC>

*Translated by B. Alekseev*